

Gary A. Hartman, D.D.S., M.S.  
Diplomate American Board of Periodontology  
240 Mustang Tr., Suite 01  
Virginia Beach, VA 23452  
(757)-498-5480

Brian S. Gurinsky, D.D.S., M.S.  
Diplomate American Board of Periodontology  
1860 Larimer Street, Suite 300  
Denver, CO 80202  
(303)-296-8527

## **The Periodontic and Orthodontic Connection**

In recent years, advances in techniques and dental materials as well as a growing public interest in developing and maintaining a healthy and attractive smile, has resulted in a greater understanding of the interrelationships between periodontics, orthodontics and restorative dentistry. With more adult patients seeking orthodontic treatment, the esthetic challenges facing patients with bone loss, occlusal wear, papilla loss, and asymmetrical marginal tissues, make an interdisciplinary approach to these cases paramount in achieving a predictable esthetic outcome. This newsletter reviews the more recent concepts and developments shared between the fields of periodontics and orthodontics, and the application of these principles in enhancing the final result of complex restorative and esthetic cases.

### **The Impacted Maxillary Canine : Surgical Techniques and Considerations**

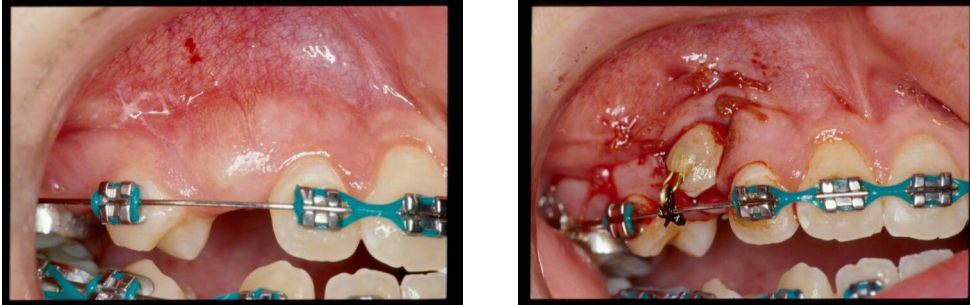
Aside from third molars, the most common intra-alveolar impaction is the maxillary canine, and is most often palatally located. The etiology of the palatally impacted canine is unknown, but it is thought that this misdirection in eruption occurs during the developmental stages of tooth formation and maturation.

According to Kokich and Matthews, there are four surgical approaches to uncovering the impacted maxillary canine, all of which depend on the location and complexity of the impaction. The simple gingivectomy, the apically positioned flap, the flap/closed eruption technique and the pre-orthodontic uncovering technique are the four techniques that are described and can be varied or combined as needed according to the case. The decision to use a resin-bonded button with a chain is also mainly dependent on the location of the impaction and whether there is potential for soft tissue closure.

### **The Labially Impacted Maxillary Canine**

Rarely can a gingivectomy be performed to uncover buccally impacted maxillary canines due to the position of the mucogingival junction. The location of the crown of the canine is most often overlapping the midroot of the lateral incisor. The goal of the uncovering procedure is to pedicle a band of keratinized tissue over the facial surface of the exposed

clinical crown. In most cases a combination of an apically positioned flap with complete bone removal to the CEJ is all that is needed prior to the orthodontist bonding a bracket and beginning orthodontic movement. If the buccal impaction is high, a resin-bonded button with a chain is secured and tied to the archwire at the surgical uncovering for orthodontic movement following initial healing.



### **The Palatally Impacted Maxillary Canine**

In recent years, Kokich and Matthews have described a technique of pre-orthodontically uncovering palatally impacted canines and classified the impaction as simple or complex based on the tooth's location and the depth of the palatal vault. If the cusp tip radiographically is near the CEJ of the adjacent teeth and not at the apices, the impaction is considered simple and may be a good candidate for pre-orthodontic uncovering. This technique is useful prior to orthodontics because it allows the tooth to erupt into a location that will help facilitate its movement when orthodontic treatment begins.

The surgery involves a full thickness flap with complete bone removal to the CEJ. A soft tissue window is made surgically in the palate and the exposed crown and window is covered with Barricade dressing to promote epithelialization around the crown and its eventual eruption.

With more complex palatal impactions, a similar approach is taken but oftentimes involves a button and chain that is bonded during the surgery that is used to anchor the Barricade dressing or is tied to the archwire for orthodontic movement if orthodontic treatment has already begun.

